

# Treatment of Vertigo

RANDY SWARTZ, M.D., *University of California, San Diego, School of Medicine, La Jolla, California*  
PAXTON LONGWELL, M.D., *Corpus Christi, Texas*

Vertigo is the illusion of motion, usually rotational motion. As patients age, vertigo becomes an increasingly common presenting complaint. The most common causes of this condition are benign paroxysmal positional vertigo, acute vestibular neuronitis or labyrinthitis, Ménière's disease, migraine, and anxiety disorders. Less common causes include vertebrobasilar ischemia and retrocochlear tumors. The distinction between peripheral and central vertigo usually can be made clinically and guides management decisions. Most patients with vertigo do not require extensive diagnostic testing and can be treated in the primary care setting. Benign paroxysmal positional vertigo usually improves with a canalith repositioning procedure. Acute vestibular neuronitis or labyrinthitis improves with initial stabilizing measures and a vestibular suppressant medication, followed by vestibular rehabilitation exercises. Ménière's disease often responds to the combination of a low-salt diet and diuretics. Vertiginous migraine headaches generally improve with dietary changes, a tricyclic antidepressant, and a beta blocker or calcium channel blocker. Vertigo associated with anxiety usually responds to a selective serotonin reuptake inhibitor. (*Am Fam Physician* 2005;71:1115-22, 1129-30. Copyright© 2005 American Academy of Family Physicians.)

► **Patient information:**  
A handout on vertigo, written by the authors of this article, is provided on page 1129.

See page 1046 for strength-of-recommendations labels.

**V**ertigo, a type of dizziness, is the illusion of motion, usually rotational motion. Associated symptoms include nausea, emesis, and diaphoresis. Vertigo should be distinguished from other types of dizziness, such as imbalance (dysequilibrium) and lightheadedness (presyncope). Most cases of vertigo can be diagnosed clinically and managed in the primary care setting.

## Vestibular Function and Vertigo

Vertigo results from acute unilateral vestibular lesions that can be peripheral (labyrinth or vestibular nerve) or central (brainstem or cerebellum). In contrast, tumors and ototoxic medications produce slowly progressive unilateral or bilateral lesions. Lesions that progress slowly or processes that affect both vestibular apparatuses equally usually do not result in vertigo.

## Diagnosis of Vertigo

Because vertigo can have multiple concurrent causes (especially in older patients), a specific diagnosis can be elusive. The duration of vertiginous episodes and the presence or absence of auditory symptoms

can help narrow the differential diagnosis (*Table 1*).<sup>1</sup> Psychiatric disorders, motion sickness, serous otitis media, cerumen impaction, herpes zoster, and seizure disorders also can present with dizziness.

The physical examination should include measurements of orthostatic vital signs and an otoscopic examination. The neurologic examination should include the Dix-Hallpike maneuver to differentiate peripheral from central vertigo<sup>2,3</sup> (*Figure 1 and Table 2*<sup>3,4</sup>).

No laboratory testing is absolutely indicated in the work-up of patients with vertigo. If hearing loss is suspected, complete audiometric testing can help distinguish vestibular pathology from retrocochlear pathology (e.g., acoustic neuroma).

Brain imaging is warranted if a tumor or stroke is suspected. The American College of Radiology<sup>5</sup> recommends magnetic resonance imaging with contrast medium when a patient presents with acute vertigo and sensorineural hearing loss. Magnetic resonance angiography can be used to evaluate the vertebrobasilar circulation.

## General Treatment Principles

### MEDICATIONS

Medications are most useful for treating acute vertigo that lasts a few hours to several

**In patients with vertigo, the neurologic examination should include the Dix-Hallpike maneuver to differentiate peripheral from central vertigo.**

## Strength of Recommendations

Key clinical recommendation	Label	References
The canalith repositioning procedure (Epley maneuver) is recommended in patients with benign paroxysmal positional vertigo.	A	18, 19, 20
The modified Epley maneuver also is effective in patients with benign paroxysmal positional vertigo.	B	16
Vestibular suppressant medication is recommended for symptom relief in patients with acute vestibular neuronitis.	C	6, 7, 8
Vestibular exercises are recommended for more rapid and complete vestibular compensation in patients with acute vestibular neuronitis.	B	14
Treatment with a low-salt diet and diuretics is recommended for patients with Ménière's disease and vertigo.	B	23, 24, 25
Effective treatments for vertiginous migraine include migraine prophylaxis (e.g., tricyclic antidepressants, beta blockers, calcium channel blockers), migraine abortive medications (e.g., sumatriptan [Imitrex]), and vestibular rehabilitation exercises.	B	13, 30, 31, 32
Selective serotonin reuptake inhibitors can relieve vertigo in patients with anxiety disorders. Because of side effects, slow titration is recommended.	B	34

A = consistent, good-quality patient-oriented evidence; B = inconsistent or limited-quality patient-oriented evidence; C = consensus, disease-oriented evidence, usual practice, opinion, or case series. See page 1046 for more information.

days (Table 3).<sup>6,7</sup> They have limited benefit in patients with benign paroxysmal positional vertigo, because the vertiginous episodes usually last less than one minute. Vertigo lasting more than a few days is suggestive of permanent vestibular injury (e.g., stroke), and medications should be stopped to allow the brain to adapt to new vestibular input.

A wide variety of medications are used to treat vertigo

and the frequently concurrent nausea and emesis. These medications exhibit various combinations of acetylcholine, dopamine, and histamine receptor antagonism. The American Gastroenterological Association recommends anticholinergics and antihistamines for the treatment of nausea associated with vertigo or motion sickness.<sup>8</sup>

Gamma-aminobutyric acid (GABA) is an inhibitory neurotransmitter in the vestibular system.<sup>6</sup> Benzodiaz-

TABLE 1  
Differential Diagnosis of Vertigo

Disorder	Duration of episodes	Auditory symptoms	Prevalence	Peripheral or central vertigo
Benign paroxysmal positional vertigo	Seconds	No	Common	Peripheral
Perilymphatic fistula (head trauma, barotrauma)	Seconds	Yes	Uncommon	Peripheral
Vascular ischemia: transient ischemic attack	Seconds to hours	Usually not	Uncommon	Central or peripheral*
Ménière's disease	Hours	Yes	Common	Peripheral
Syphilis	Hours	Yes	Uncommon	Peripheral
Vertiginous migraine	Hours	No	Common	Central
Labyrinthine concussion	Days	Yes	Uncommon	Peripheral
Labyrinthitis	Days	Yes	Common	Peripheral
Vascular ischemia: stroke	Days	Usually not	Uncommon	Central or peripheral*
Vestibular neuronitis	Days	No	Common	Peripheral
Anxiety disorder	Variable	Usually not	Common	Unspecified
Acoustic neuroma	Months	Yes	Uncommon	Peripheral
Cerebellar degeneration	Months	No	Uncommon	Central
Cerebellar tumor	Months	No	Uncommon	Central
Multiple sclerosis	Months	No	Uncommon	Central
Vestibular ototoxicity	Months	Yes	Uncommon	Peripheral

\*—Vertigo can be caused by vascular ischemia in the central vertebrobasilar circulation or the peripheral circulation to the vestibular nerve and labyrinth.<sup>1</sup>

TABLE 2

**Clues to Distinguish Between Peripheral and Central Vertigo**

Clues	Peripheral vertigo	Central vertigo
Findings on Dix-Hallpike maneuver		
Latency of symptoms and nystagmus	2 to 40 seconds	None
Severity of vertigo	Severe	Mild
Duration of nystagmus	Usually less than 1 minute	Usually more than 1 minute
Fatigability*	Yes	No
Habituation†	Yes	No
Other findings		
Postural instability	Able to walk; unidirectional instability	Falls while walking; severe instability
Hearing loss or tinnitus	Can be present	Usually absent
Other neurologic symptoms	Absent	Usually present

\*—Response remits spontaneously as position is maintained.

†—Attenuation of response as position repeatedly is assumed.

Information from references 3 and 4.

epines enhance the action of GABA in the central nervous system (CNS) and are effective in relieving vertigo and anxiety.

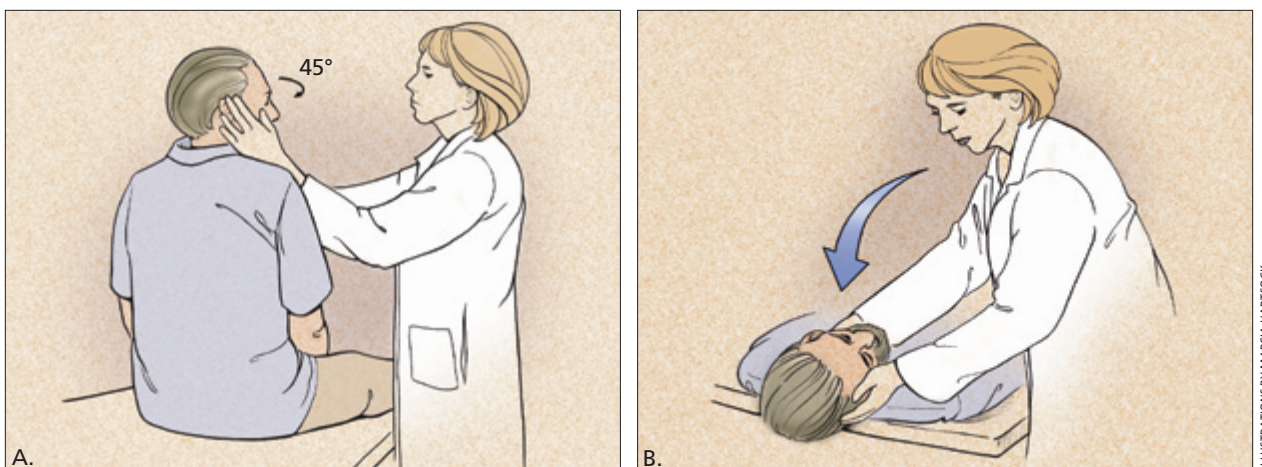
Older patients are at particular risk for side effects of vestibular suppressant medications (e.g., sedation, increased risk of falls, urinary retention). These patients also are more likely to experience drug interactions (i.e., additive effects with other CNS depressants).

**VESTIBULAR REHABILITATION EXERCISES**

Vestibular rehabilitation exercises commonly are included in the treatment of vertigo<sup>9,10</sup> (see *patient information handout*). These exercises train the brain to use

alternative visual and proprioceptive cues to maintain balance and gait. It is necessary for a patient to reexperience vertigo so that the brain can adapt to a new baseline of vestibular function. After acute stabilization of the patient with vertigo, use of vestibular suppressant medications should be minimized to facilitate the brain's adaptation to new vestibular input.

A randomized, controlled trial (RCT)<sup>11</sup> of 143 primary care patients with dizziness and vertigo showed that vestibular rehabilitation exercises improved nystagmus, postural control, movement-provoked dizziness, and subjective indexes of symptoms and distress. Another RCT<sup>12</sup> evaluated the effectiveness of home vestibular



**Figure 1.** Dix-Hallpike maneuver (used to diagnose benign paroxysmal positional vertigo). This test consists of a series of two maneuvers: With the patient sitting on the examination table, facing forward, eyes open, the physician turns the patient's head 45 degrees to the right (A). The physician supports the patient's head as the patient lies back quickly from a sitting to supine position, ending with the head hanging 20 degrees off the end of the examination table. The patient remains in this position for 30 seconds (B). Then the patient returns to the upright position and is observed for 30 seconds. Next, the maneuver is repeated with the patient's head turned to the left. A positive test is indicated if any of these maneuvers provide vertigo with or without nystagmus.

TABLE 3

**Medications Commonly Used In Patients with Acute Vertigo and Associated Nausea and Emesis**

<i>Medication</i>	<i>Dosage</i>	<i>Sedation</i>	<i>Antiemesis</i>	<i>Pregnancy category</i>
Mecizine* (Antivert)	12.5 to 50 mg orally every 4 to 8 hours	++	+	B
Dimenhydrinate* (Dramamine)	25 to 100 mg orally, IM, or IV every 4 to 8 hours	+	++	B
Diazepam (Valium)	2 to 10 mg orally or IV every 4 to 8 hours	++	+	D
Lorazepam (Ativan)	0.5 to 2 mg orally, IM, or IV every 4 to 8 hours	++	+	D
Metoclopramide (Reglan)	5 to 10 mg orally every 6 hours 5 to 10 mg by slow IV every 6 hours	+	+++	B
Prochlorperazine (Compazine)	5 to 10 mg orally or IM every 6 to 8 hours 25 mg rectally every 12 hours 5 to 10 mg by slow IV over 2 minutes	+	+++	C
Promethazine (Phenergan)	12.5 to 25 mg orally, IM, or rectally every 4 to 12 hours	+++	++	C

\*—Available over the counter.

+ = mild; ++ = moderate; +++ = prominent; IM = intramuscular; IV = intravenous.

Information from references 6 and 7.

rehabilitation in patients with chronic vertigo with a peripheral vestibular etiology. This trial<sup>12</sup> showed a significant reduction of vertigo and an increase in the ability to perform activities of daily living independently.

A retrospective case series<sup>13</sup> assessed the efficacy of physical therapy in patients who had vestibular and balance disorders with or without a history of migraine. Both groups showed significant alleviation of dizziness and improvement of balance and gait. Vestibular exercises also have been shown to improve postural control during the first month after acute unilateral vestibular lesions resulting from vestibular neuronitis.<sup>14</sup>

### Treatment of Specific Disorders

#### BENIGN PAROXYSMAL POSITIONAL VERTIGO

Benign paroxysmal positional vertigo is caused by calcium debris in the semicircular canals (canalithiasis), usually the posterior canal. Medications generally are not recommended for the treatment of this condition.

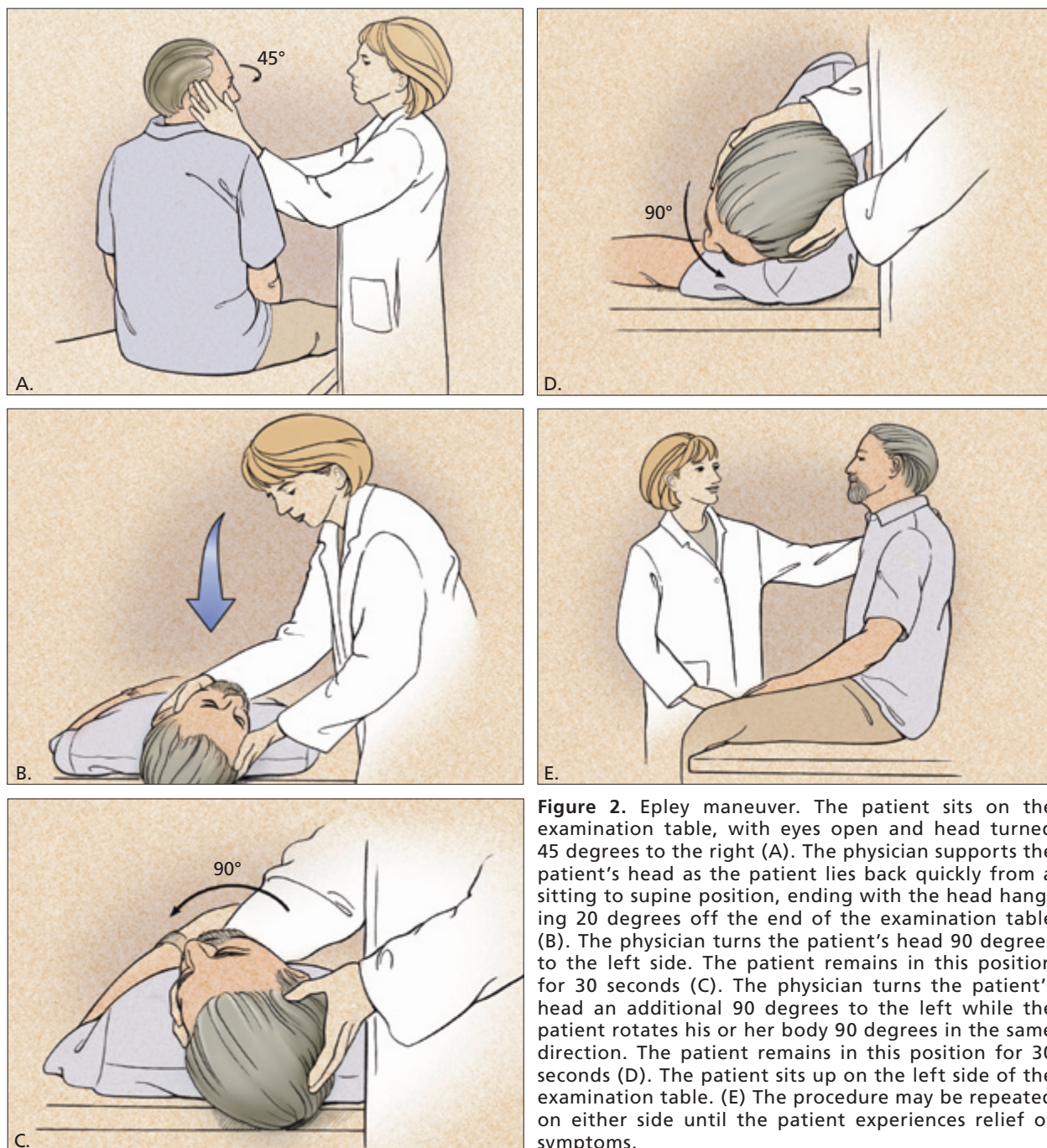The vertigo improves with head rotation maneuvers that displace free-moving calcium deposits back to the vestibule. Maneuvers include the canalith repositioning procedure or Epley maneuver<sup>15</sup> and the modified Epley maneuver<sup>16</sup> (Figure 2). The modified Epley maneuver can be performed at home.

Patients may need to remain upright for 24 hours after canalith repositioning to prevent calcium deposits from returning to the semicircular canals, although this

measure is not universally recommended. Contraindications to canalith repositioning procedures include severe carotid stenosis, unstable heart disease, and severe neck disease, such as cervical spondylosis with myelopathy or advanced rheumatoid arthritis.<sup>17</sup>

Canalith repositioning has been found to be effective in patients with benign paroxysmal positional vertigo. The initial report<sup>15</sup> on the Epley maneuver indicated an 80 percent success rate after a single treatment and a 100 percent success rate with repeated treatments. Two subsequent RCTs<sup>18,19</sup> reported success rates of 50 to 90 percent. A Cochrane systematic review<sup>20</sup> concluded that the Epley maneuver is a safe treatment that is likely to result in improvement of symptoms and conversion from a positive to negative Dix-Hallpike maneuver. However, the review<sup>20</sup> noted that no long-term assessment was performed in either RCT<sup>18,19</sup> on the use of the Epley maneuver. A study<sup>16</sup> of 54 patients with benign paroxysmal positional vertigo found that the modified Epley maneuver was effective in resolving vertigo symptoms after one week of treatment. This study, however, has been criticized for inadequate randomization and lack of blinding of outcome assessors (patient self-report of symptoms).<sup>20</sup>

One study<sup>21</sup> on the long-term effects of canalith repositioning procedures in patients with benign paroxysmal positional vertigo reported a recurrence rate of about 15 percent per year. Another study<sup>22</sup> reported recur-



**Figure 2.** Epley maneuver. The patient sits on the examination table, with eyes open and head turned 45 degrees to the right (A). The physician supports the patient's head as the patient lies back quickly from a sitting to supine position, ending with the head hanging 20 degrees off the end of the examination table (B). The physician turns the patient's head 90 degrees to the left side. The patient remains in this position for 30 seconds (C). The physician turns the patient's head an additional 90 degrees to the left while the patient rotates his or her body 90 degrees in the same direction. The patient remains in this position for 30 seconds (D). The patient sits up on the left side of the examination table. (E) The procedure may be repeated on either side until the patient experiences relief of symptoms.

rence rates of 20 percent at 20 months and 37 percent at 60 months.

#### VESTIBULAR NEURONITIS AND LABYRINTHITIS

Acute inflammation of the vestibular nerve is a common cause of acute, prolonged vertigo. Associated hearing loss occurs if the labyrinth is involved. The vertigo usu-

ally lasts a few days and resolves within several weeks. Many cases of vestibular neuronitis or labyrinthitis are attributed to self-limited viral infections,<sup>7</sup> although specific proof of a viral etiology rarely is identified.<sup>1</sup>

Treatment focuses on symptom relief using vestibular suppressant medications,<sup>6-8</sup> followed by vestibular exercises.<sup>14</sup> Vestibular compensation occurs more rapidly and

more completely if the patient begins twice-daily vestibular rehabilitation exercises as soon as tolerated after the acute vertigo has been alleviated with medications.<sup>7,11</sup>

### MÉNIÈRE'S DISEASE

Ménière's disease (or endolymphatic hydrops) presents with vertigo, tinnitus (low tone, roaring, or blowing quality), fluctuating low-frequency sensorineural hearing loss, and a sense of fullness in the ear. In this disorder, impaired endolymphatic filtration and excretion in the inner ear leads to distention of the endolymphatic compartment.

Treatment lowers endolymphatic pressure. Although a low-salt diet (less than 1 to 2 g of salt per day) and diuretics (most commonly the combination of hydrochlorothiazide and triamterene [Dyazide]) often reduce the vertigo, these measures are less effective in treating hearing loss and tinnitus.<sup>23,24</sup> Note, however, that the authors of a systematic review<sup>25</sup> of treatments for Ménière's disease criticized the statistical analysis of the frequency of vertigo episodes in one of the studies.<sup>23</sup>

In rare cases, surgical intervention, such as decompression with an endolymphatic shunt or cochleosacculotomy, may be required when Ménière's disease is resistant to treatment with diet and diuretics. Ablation of the vestibular hair cells with intratympanic injection of gentamicin also may be effective.<sup>26</sup> Surgery usually is reserved for patients with severe, refractory Ménière's disease.

### VASCULAR ISCHEMIA

The sudden onset of vertigo in a patient with additional neurologic symptoms (e.g., diplopia, dysarthria, dysphagia, ataxia, weakness) suggests the presence of vascular ischemia.

---

### The Authors

RANDY SWARTZ, M.D., is voluntary associate clinical professor in the Department of Family and Preventive Medicine at the University of California, San Diego, School of Medicine, La Jolla, Calif., and assistant program director at the Scripps Family Practice Residency Program, Chula Vista, Calif. Dr. Swartz graduated from the University of Texas–Houston Medical School and completed residencies in family practice and psychiatry at the Harbor–UCLA (University of California, Los Angeles) Medical Center, Torrance, Calif.

PAXTON LONGWELL, M.D., is a neurologist in private practice in Corpus Christi, Tex. He graduated from the University of Texas–Houston Medical School and completed a residency in neurology at Harbor–UCLA Medical Center.

*Address correspondence to Randy Swartz, M.D., 450 Fourth Ave., Suite 201, Chula Vista, CA 91910 (e-mail: swartz.john2@scrippshealth.org). Reprints are not available from the authors.*

Treatment of transient ischemic attack and stroke includes preventing future events through blood pressure control, cholesterol-level lowering, smoking cessation, inhibition of platelet function (e.g., aspirin, clopidogrel [Plavix], aspirin-dipyridamole [Aggrenox]) and, possibly, anticoagulation (warfarin [Coumadin]).

Acute vertigo caused by a cerebellar or brainstem stroke is treated with vestibular suppressant medication and minimal head movement for the first day. As soon as tolerated, medication should be tapered, and vestibular rehabilitation exercises should be initiated.<sup>8,10</sup>

Placement of vertebrobasilar stents may be considered in a patient with symptomatic critical vertebral artery stenosis that is refractory to medical management.<sup>27</sup> Rarely, infarction or hemorrhage in the cerebellum or brainstem may present with acute vertigo as the only neurologic symptom.<sup>28</sup> Given the risk of brainstem compression with a large cerebellar stroke, neurosurgical decompression may be indicated.

### MIGRAINE HEADACHES

Epidemiologic evidence shows a strong association between vertigo and migraine.<sup>29</sup> Diagnostic criteria have been proposed to provide a more specific definition of vertiginous migraine.<sup>29</sup> Diagnostic accuracy is important because vertiginous migraine may respond better to migraine treatments than to other interventions.

One retrospective review<sup>30</sup> found that migraine treatments were effective in about 90 percent of patients with migraine-associated vertigo. Treatments included dietary changes (i.e., reduction or elimination of aspartame, chocolate, caffeine, or alcohol), lifestyle changes (i.e., exercise, stress reduction, improvements in sleep patterns), vestibular rehabilitation exercises, and medications (e.g., benzodiazepines, tricyclic antidepressants, beta blockers, selective serotonin reuptake inhibitors [SSRIs], calcium channel blockers, antiemetics).

Another retrospective chart review<sup>31</sup> demonstrated that stepwise treatment of migraine-associated dizziness (vertigo or dysequilibrium) resulted in complete or dramatic reduction of symptoms in 58 of 81 patients (72 percent). The stepwise treatment consisted of initiating dietary changes, then adding nortriptyline (Pamelor) if needed, then adding atenolol or a calcium channel blocker if needed and, finally, consultation with a neurologist if needed.

A survey<sup>32</sup> of 53 patients with migraine at a university-based headache clinic found that the efficacy of medications in treating migraine-associated dizziness was directly correlated with their ability to alleviate migraines. This correlation was strongest in patients

with vertigo who were receiving migraine-abortive medications (most significantly, sumatriptan [Imitrex]).

#### PSYCHIATRIC DISORDERS

Vertigo commonly is associated with anxiety disorders (e.g., panic disorder, generalized anxiety disorder) and, less frequently, depression.<sup>33,34</sup> Hyperventilation usually occurs and can result in hypocapnia with reversible cerebral vasoconstriction. Hyperventilation and hypocapnia may be accompanied by dyspnea, chest pain, palpitations, or paresthesias.

Subclinical vestibular dysfunction has been measured in patients with anxiety disorders or depression, most commonly panic disorder with moderate to severe agoraphobia.<sup>33</sup> Conversely, classic vertigo resulting from more ostensible vestibular pathology usually induces severe anxiety symptoms and thus can be hard to distinguish from a primary anxiety disorder.

Vestibular suppressants and benzodiazepines most frequently are used to treat dizziness that is associated with anxiety disorder, but these medications provide only transient or inadequate relief.<sup>34</sup> SSRIs such as citalopram (Celexa), fluoxetine (Prozac), paroxetine (Paxil), and sertraline (Zoloft) may provide better relief.

A review<sup>34</sup> of 68 patients from a research database at a university neurotology center evaluated open-label SSRI treatment of dizziness associated with psychiatric symptoms (with or without neurotologic illness). Significant improvement of dizziness occurred in 38 patients (63 percent); however, 15 (25 percent) of the 60 patients experienced intolerable side effects. Because some side effects of SSRIs (e.g., nausea, sedation, dizziness) may be more intolerable for patients who have dizziness in association with psychiatric symptoms, slow titration should be used.<sup>34</sup>

Other medications that are effective in patients with anxiety disorders or depression, such as norepinephrine-serotonin reuptake inhibitors (e.g., venlafaxine [Effexor]) and tricyclic antidepressants (e.g., nortriptyline, desipramine [Norpramin]), have not been evaluated in patients with concomitant vertigo.

Nonpharmacologic treatments for anxiety disorders, such as cognitive behavior therapy, may be helpful. A small prospective RCT of vestibular rehabilitation combined with cognitive behavior therapy to reduce anxiety in older patients with dizziness showed that this combination of treatments improved gait speed and dizziness symptoms but did not improve anxiety or depression.<sup>35</sup>

#### PHYSIOLOGIC VERTIGO

Motion sickness<sup>9</sup> is attributed to an incongruence in the sensory input from the vestibular, visual, and somato-

sensory systems. Motion sickness occurs while riding in a car, boat, or airplane if the vestibular and somatosensory systems sense movement, but the visual system does not.

On the first sensation of motion sickness, efforts should be made to bring vestibular, visual, and somatosensory input back in congruence. For example, a person on a boat who starts to feel seasick should immediately watch the horizon. Seasickness can be prevented by applying a scopolamine patch (Transderm-Scop) behind one ear at least four hours before boating.<sup>8,36</sup>

The authors indicate that they do not have any conflicts of interest. Sources of funding: none reported.

Members of various family medicine departments develop articles for "Practical Therapeutics." This article is one in a series coordinated by the Department of Family Medicine and Preventive Medicine at the University of California, San Diego, School of Medicine. Guest editor of the series is Tyson Ikeda, M.D.

#### REFERENCES

- Hotson JR, Baloh RW. Acute vestibular syndrome. *N Engl J Med* 1998;339:680-5.
- Dix MR, Hallpike CS. The pathology, symptomatology and diagnosis of certain common disorders of the vestibular system. *Proc R Soc Med* 1952;45:341-54.
- Furman JM, Cass SP. Benign paroxysmal positional vertigo. *N Engl J Med* 1999;341:1590-6.
- Disorders of equilibrium. In: Greenberg DA, Aminoff MJ, Simon RP. *Clinical neurology*. 5th ed. New York: McGraw-Hill, 2002:95-126.
- Hasso AN, Drayer BP, Anderson RE, Braffman B, Davis PC, Deck MD, et al. Vertigo and hearing loss. *American College of Radiology. ACR Appropriateness Criteria. Radiology* 2000;215(suppl):471-8.
- Hain TC, Uddin M. Pharmacological treatment of vertigo. *CNS Drugs* 2003;17:85-100.
- Baloh RW. Vestibular neuritis. *N Engl J Med* 2003;348:1027-32.
- Quigley EM, Hasler WL, Parkman HP. AGA technical review on nausea and vomiting. *Gastroenterology* 2001;120:263-86.
- Fife TD. Episodic vertigo. In: Rakel RE, ed. *Conn's Current therapy*, 1999: latest approved methods of treatment for the practicing physician. 51st ed. Philadelphia: Saunders, 1999:923-30.
- Baloh RW. Vertigo in older people. *Curr Treat Options Neurol* 2000;2:81-9.
- Yardley L, Beech S, Zander L, Evans T, Weinman J. A randomized controlled trial of exercise therapy for dizziness and vertigo in primary care. *Br J Gen Pract* 1998;48:1136-40.
- Cohen HS, Kimball KT. Increased independence and decreased vertigo after vestibular rehabilitation. *Otolaryngol Head Neck Surg* 2003;128:60-70.
- Wrisley DM, Whitney SL, Furman JM. Vestibular rehabilitation outcomes in patients with a history of migraine. *Otol Neurotol* 2002;23:483-7.
- Strupp M, Arbusow V, Maag KP, Gall C, Brandt T. Vestibular exercises improve central vestibulospinal compensation after vestibular neuritis. *Neurology* 1998;51:838-44.
- Epley JM. The canalith repositioning procedure: for treatment of benign paroxysmal positional vertigo. *Otolaryngol Head Neck Surg* 1992;107:399-404.

## Vertigo

16. Radtke A, Neuhauser H, von Brevern M, Lempert T. A modified Epley's procedure for self-treatment of benign paroxysmal positional vertigo. *Neurology* 1999;53:1358-60.
17. Humphriss RL, Baguley DM, Sparkes V, Peerman SE, Moffat DA. Contraindications to the Dix-Hallpike manoeuvre: a multidisciplinary review. *Int J Audiol* 2003;42:166-73.
18. Lynn S, Pool A, Rose D, Brey R, Suman V. Randomized trial of the canalith repositioning procedure. *Otolaryngol Head Neck Surg* 1995;113:712-20.
19. Froehling DA, Bowen JM, Mohr DN, Brey RH, Beatty CW, Wollan PC, et al. The canalith repositioning procedure for the treatment of benign paroxysmal positional vertigo: a randomized controlled trial. *Mayo Clin Proc* 2000;75:695-700.
20. Hilton M, Pinder D. The Epley (canalith repositioning) manoeuvre for benign paroxysmal positional vertigo. *Cochrane Database Syst Rev* 2004;(3):CD003162.
21. Nunez RA, Cass SP, Furman JM. Short- and long-term outcomes of canalith repositioning for benign paroxysmal positional vertigo. *Otolaryngol Head Neck Surg* 2000;122:647-52.
22. Sakaida M, Takeuchi K, Ishinaga H, Adachi M, Majima Y. Long-term outcome of benign paroxysmal positional vertigo. *Neurology* 2003;60:1532-4.
23. Van Deelen GW, Huizing EH. Use of a diuretic (Dyazide) in the treatment of Meniere's disease. A double-blind cross-over placebo-controlled study. *ORL J Otorhinolaryngol Relat Spec* 1986;48:287-92.
24. Santos PM, Hall RA, Snyder JM, Hughes LF, Dobie RA. Diuretic and diet effect on Meniere's disease evaluated by the 1985 Committee on Hearing and Equilibrium guidelines. *Otolaryngol Head Neck Surg* 1993;109:680-9.
25. James A, Thorp M. Meniere's disease. *Clin Evid* 2003;(9):565-73.
26. Blakley BW. Update on intratympanic gentamicin for Meniere's disease. *Laryngoscope* 2000;110(2 pt 1):236-40.
27. Levy EI, Hanel RA, Bendok BR, Boulos AS, Hartney ML, Guterman LR, et al. Staged stent-assisted angioplasty for symptomatic intracranial vertebrobasilar artery stenosis. *J Neurosurg* 2002;97:1294-301.
28. Norrving B, Magnusson M, Holtas S. Isolated acute vertigo in the elderly; vestibular or vascular disease? *Acta Neurol Scand* 1995;91:43-8.
29. Neuhauser H, Leopold M, von Brevern M, Arnold G, Lempert T. The interrelations of migraine, vertigo, and migrainous vertigo. *Neurology* 2001;56:436-41.
30. Johnson GD. Medical management of migraine-related dizziness and vertigo. *Laryngoscope* 1998;108(1 pt 2):1-28.
31. Reploeg MD, Goebel JA. Migraine-associated dizziness: patient characteristics and management options. *Otol Neurotol* 2002;23:364-71.
32. Bikhazi P, Jackson C, Ruckenstein MJ. Efficacy of antimigrainous therapy in the treatment of migraine-associated dizziness. *Am J Otol* 1997;18:350-4.
33. Jacob RG, Furman JM, Durrant JD, Turner SM. Panic, agoraphobia, and vestibular dysfunction. *Am J Psychiatry* 1996;153:503-12.
34. Staab JP, Ruckenstein MJ, Solomon D, Shepard NT. Serotonin reuptake inhibitors for dizziness with psychiatric symptoms. *Arch Otolaryngol Head Neck Surg* 2002;128:554-60.
35. Johansson M, Akerlund D, Larsen HC, Andersson G. Randomized controlled trial of vestibular rehabilitation combined with cognitive-behavioral therapy for dizziness in older people. *Otolaryngol Head Neck Surg* 2001;125:151-6.
36. Flake ZA, Scalley RD, Bailey AG. Practical selection of antiemetics. *Am Fam Physician* 2004;69:1169-74.